

Thymic Hormones in Human Fetal Skin Epidermis

Z. S. Khlystova, I. I. Kalinina, and V. Kh. Khavinson

Translated from *Byulleten' Eksperimental'noi Biologii i Meditsiny*, Vol. 133, No. 2, pp. 231-233, February, 2002
Original article submitted November 8, 2001

Thymic hormone thymalin is detected in young epidermal cells of human fetuses. Its content varies with gestation age. Maturation of keratinocytes in the epidermis is paralleled by a decrease in the population of young thymalin-positive cells. By birth they are located on the basal membrane and in some adjacent layers. This regularity was seen in different parts of the body.

Key Words: *thymalin; human fetal skin*

Defense cellular immune mechanisms in the skin are little studied. Skin epidermis contains lymphocytes and other cells, *e. g.* Langerhans cells (LC) which can participate in immune processes. LC are dendritic cells not related to keratinocytes and originating from myeloid precursor cells. LC are characterized as epidermal dendritic macrophages, which can accumulate the antigen and stimulate T helper lymphocytes [8]. In contrast to common dendritic cells, LC do not promote B cell proliferation.

Apart from defense function, epidermal keratinocytes exhibit secretory activity. Cytokins indirectly participating in immune processes were isolated from animal epidermis [1-3]. It was unclear whether the epidermis contains thymic hormones modulating extrathymic T cell differentiation. It was hypothesized that lymphocytes migrate and undergo differentiation in the skin [4]. These mechanisms underlie the formation of cell lymphomas. Some authors did not detect thymic hormones (thymalin, thymopoietin) in the epidermis with monoclonal antibodies and therefore denied the presence of thymic hormone in the epidermis [13]. On the other hand, the presence of hemopoietin in fetal calf skin epidermis was demonstrated [10]. The ability of keratinocytes to synthesize thymic hor-

mone disappears after birth. Foreign authors showed that thymic reticuloepithelium produced several hormones (thymuline, thymosine α -1, *etc.*) [10, 12], which are widely used in clinical practice abroad. Several thymic preparations (thymomimetics) were obtained in Russia during the recent decade [5,6], which differ by the number and sequence of amino acid residues from the known agents. One of these preparations is thymalin (a 1000-5000 D polypeptide consisting of 38 amino acid residues), which is now characterized and approved for clinical use as an immunomodulator for correction of immunodeficiency. Thymalin has never been detected in the skin epidermis.

The aim of our study was to elucidate whether thymalin is present in human fetal skin epidermis and to identify thymalin-producing cells, *i. e.* to detect hormonal relationships between the thymus and skin, indicating the possibility of extrathymic T cell differentiation in the skin.

MATERIALS AND METHODS

Thymic reticuloepithelium and skin epithelium of 6-30-week human fetuses was examined. Skin epidermis was taken from the back, palm, and rectum at the interface between the skin and rectal epithelium.

Thymalin was detected on cryostat sections using antithymalin serum, prepared by the method of I. V. Moskvicheva [7]. Antiserum (maximum

Laboratory of Embryonal Histogenesis, Institute of Human Morphology, Russian Academy of Medical Sciences, Moscow

titer 1:3200) was used in the indirect hemagglutination test.

Cryostat sections (4-5 μ) were prepared from specimens frozen in liquid nitrogen. The sections were dried on air, fixed in cold (5°C) acetone, and washed in cold buffered saline (pH 7.4) for 15 min. Then the sections were incubated with rabbit anti-thymalin antiserum for 40 min and washed in cold buffered saline (3 \times 15 min). The sections were incubated with FITC-labeled asinine serum to rabbit globulins for 20 min. In order to reduce nonspecific adsorption, the conjugates were treated with human liver powder before incubation with the sections. Control sections were treated with intact serum or buffered saline. The sections were incubated in a humid chamber at 18-20°C and examined under a Lumam-P-3 fluorescent microscope.

RESULTS

Thymalin is present in thymic epithelium of 5-6-week fetuses, *i. e.* at the primordial stage before its population with lymphocytes. Initially, thymalin-producing cells are diffusely located in stratified

epithelium cord, and by week 30 of fetal development they are concentrated mainly in the thymus medulla (Fig. 1, *a*). Thymalin was not found in the rectal epithelium and hence, we consider that thymalin is characteristic only of ectodermal epithelium, in particular thymic cells and skin keratinocytes.

Skin of 8-10-week human fetus contains no hair follicles, but the thickness of its epidermis depends on its topography. The epidermis on the back is thin, with a lesser number of cell layers than palm epidermis. However, both have no horny layer and all keratinocytes are just poorly differentiated elements of the germinal layer. Thymalin is clearly discernible in both sites of the epidermis (Fig. 1, *b*, *c*). In the rectum thymalin-positive cells are present only in skin epithelium.

By 23 weeks epidermal cells are differentiated. The protective horny and germinal layers consisting of young keratinocytes gradually appear. This new state of the cells is associated with accumulation of keratin and loss of thymalin-producing capacity. At this term thymalin-positive cells are clearly seen in the basal epidermal layers (Fig. 1,

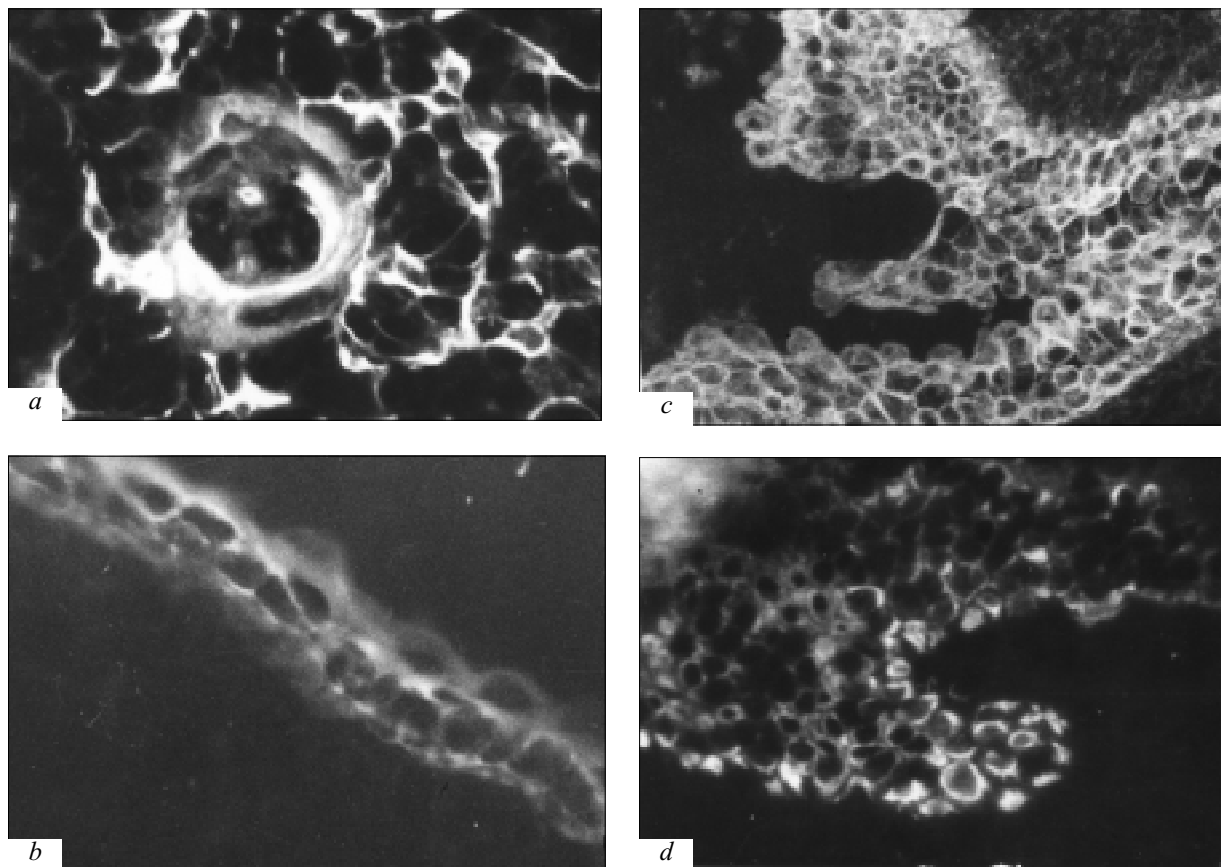


Fig. 1. Thymalin in thymic medullary reticuloepithelium of 30-week fetus (*a*), back skin epidermis of an 8-week fetus (*b*), and palm skin epidermis of 10- (*c*) and 23-week (*d*) human fetuses. Indirect Coons' method, $\times 800$ (*a*, *b*), $\times 400$ (*c*, *d*).

d). This regularity is observed in the epidermis of all studied skin samples and is more clearly seen by birth.

Hence, our findings indicate that human fetal skin epidermis contains thymic hormone thymalin. It is present in the cytoplasm of young keratinocytes, while horny layer epidermal cells do not produce thymalin. With appearance of the horny layer, the population of young cells decreases and they concentrate close to the basal membrane. This regularity is observed in the epidermis irrespective of its topography. It seems that during divergent development of stratified skin and thymic epithelium from a common source (ectoderm) the epithelium retains some preformed histogenetic signs. The capacity to secrete polypeptides (including thymalin) ensuring extrathymic differentiation of T lymphocytes is one of the common signs. The study showed that prerequisites of future cooperation of cells (LC, lymphocytes) and thymic hormones are created in human skin as early as during the embryonal period. Not only thymic epithelium, but also young epidermocytes can serve as the source of thymic hormones.

REFERENCES

1. V. Ya. Arion, *Immunobiology of Thymic Hormones* [in Russian], Kiev (1989), 103-125.
2. V. Ya. Arion and O. V. Belova, *Int. Immunorehabil.*, No. 2, 34-36 (2000).
3. I. V. Zimina, Yu. M. Mozhukhin, and V. Ya. Arion, *Immunologiya*, No. 1, 8-13 (1994).
4. *Clinical Immunology. Manual for Physicians* [in Russian], Ed. V. I. Sokolov, Moscow (1998), pp. 209-212.
5. V. G. Morozov and V. Kh. Khavinson, *Immunobiology of Thymic Hormones* [in Russian], Kiev (1989), pp. 125-142.
6. V. G. Morozov, V. Kh. Khavinson, and V. V. Malinin, *Peptide Thymomimetics* [in Russian], St. Petersburg (2000).
7. I. V. Moskvicheva, G. A. Ryzhak, V. G. Morozov, *et al.*, *Mikrobiologiya*, No. 3, 74-78 (1985).
8. M. V. Pashchenko and B. V. Pinegin, *Immunologiya*, No. 4, 7-16 (2001).
9. Z. S. Khlystova, I. I. Kalinina, S. P. Shmeleva, *et al.*, *Byull. Eksp. Biol. Med.*, **130**, No. 10, 453-456 (2000).
10. T. K. Audya and G. Goldstein, *Ann. N. Y. Acad. Sci.*, **548**, 233-240 (1988).
11. T. F. Bash, M. Dardenne, T. M. Pleau, *et al.*, *Nature*, **266**, 55-56 (1976).
12. A. L. Goldstein, T. L. Low, M. Macadoo, *et al.*, *Proc. Natl. Acad. Sci. USA*, **74**, 725-729 (1977).
13. J. F. Nicolas, C. Auger, M. Dardenne, *et al.*, *Thymus*, **12**, No. 3, 187-201 (1988/1989).